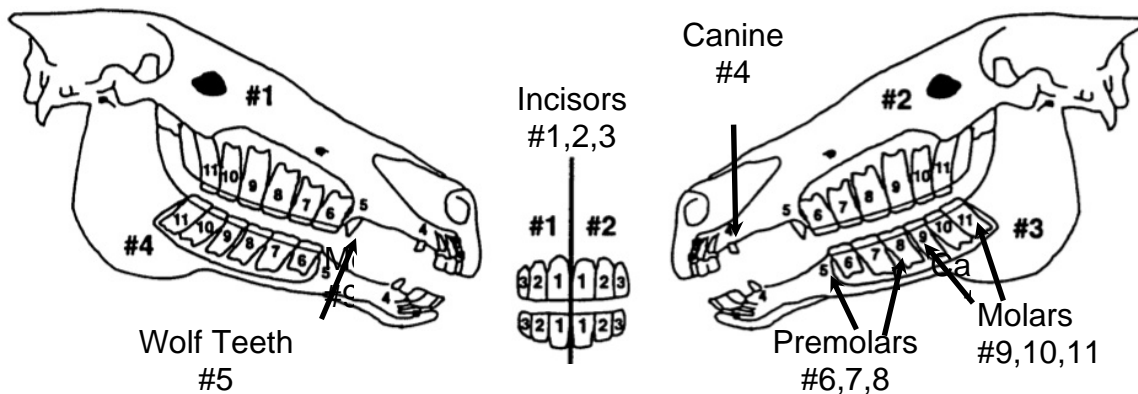


Equine Dentistry - Part 2  
 Congenital & Developmental Tooth Disorders of the Growing Horse  
*Ernie Martinez II, DVM*

The oral cavity of a young growing horse is undergoing constant change. Unlike humans, horses have hypsodont teeth that are constantly erupting. From the time a foal is born to the time the horse is an adult, the number of teeth increases from 0-6 as a foal to 36-44 as a full mouthed adult. The average horse has a full mouth of 36-44 teeth (4 rows of 11) by the age of 4 years. During the first four years, it is important to routinely evaluate the oral cavity for congenital and developmental disorders. If congenital and developmental disorders are not identified and addressed early, they may lead to more severe acquired disorders.

A newborn foal is born with few teeth. The first incisors may be present at birth or can be just below the gingival surface. The first incisors typically erupt through the gingiva around 6-8 days of life. All of the incisors should be present by 6-9 months of age. The same is true for the 2nd, 3rd, and 4th pre-molars. They may be present at birth but they are generally exposed by two weeks of age. Three permanent molars erupt caudal(behind) to the premolars at 1, 2 & 3.5-4 years respectively.



Congenital dental disorders can be diagnosed at birth or within the first few weeks as the deciduous teeth begin to erupt. Common congenital disorders include overjet, overbite, underjet, and wry nose. Overjet to some degree is normal in most horses. In this case the front (rostral) edge of the upper incisor is farther forward than the front (rostral) edge of the lower incisor. A severe case of overjet can become an overbite where the entire upper incisor sits farther forward than the lower incisor. This is commonly called “parrot mouth.” An overbite rarely causes problems with biting and chewing (prehension and mastication) of food. Normal incisors wear down due to contact with the opposite tooth during chewing. Special care may be needed during dental examinations to maintain proper incisor balance due to unopposed apposition of some or all of the incisors. Wry nose is forward (rostral) deviation of the maxilla and the associated nasal septal deviation. It can result in disturbances to nasal airflow and uneven eruption of the incisors and cheek teeth. Mild cases may correct on their own

but severe cases could require surgical intervention. These cases require frequent dental care to balance incisor and cheek teeth overgrowth; and while the treatments are temporary, these conditions are permanent.

Developmental dental disorders can involve the deciduous teeth or the permanent teeth. Disorders include abnormal development, abnormal positioning, extra or supernumerary teeth, and lack of teeth or hypodontia. Abnormal development or dental dysplasia may result in abnormally shaped teeth that do not fit properly with the incisor or cheek teeth row. This can cause uneven wear, disturbed eruption and periodontal disease from food packing. Other abnormal dental developments can include defects of enamel formation resulting in abnormally shaped teeth. The causes of dental dysplasias can include genetics, in utero treatments, systemic diseases in the neonate, and trauma to the oral cavity and surrounding structures. Developmental dysplasias can be identified with routine oral examinations and radiographic evaluations.

Supernumerary teeth, or extra teeth, most commonly develop at the edges of the teeth margins. For example, at the outside of the upper and lower incisor rows and at the beginning or end of the cheek teeth row. They can occur in line with normal teeth or can be found on the lingual or buccal aspects of the normal cheek teeth row. Supernumerary teeth may arise from excessive tooth development (odontogenic capacity) or from the splitting of a tooth bud. Supernumerary incisors are usually normal teeth and typically appear during permanent tooth eruption. For this reason they are often confused with retained deciduous caps and radiographs may be needed to differentiate the two. Supernumerary incisors can result in over crowding, displacement of normal teeth and uneven wear. They can usually be managed with routine reduction twice a year.

Supernumerary cheek teeth most commonly develop at the caudal aspect of the maxillary cheek teeth rows (the back of the upper rows.) But they can also occur medially, laterally or rostrally to the upper and lower cheek teeth rows. Supernumerary cheek teeth are commonly seen as the normal permanent cheek teeth are erupting. Their abnormal positions result in large interdental spaces, feed packing and painful periodontal disease. The teeth will most likely erupt unopposed causing a space to form (diastema) between itself and adjacent teeth. Oral extraction is the preferable option if possible. If this is not possible, the crown is reduced to prevent soft tissue trauma and the diastema is widened to prevent food packing and periodontal disease. This can be difficult in the back of the mouth. Caudal supernumerary teeth should be carefully evaluated with intra-oral tools and radiography to determine their effect on adjacent teeth and nearby sinuses.

Hypodontia, or reduced tooth numbers, is a developmental abnormality of equine teeth. It is fairly uncommon in horses and is most commonly caused by trauma, disease or excessive wear. The condition usually affects the permanent teeth and the main concern is balance or reduction of the opposite tooth as it erupts unopposed.

The horse has 24 deciduous teeth to shed, 12 incisors and 12 premolars. Retained deciduous teeth can cause several problems in the growing equine mouth. Retained deciduous incisors can cause displacement of erupting permanent incisors and if retained long enough, they can cause permanent changes to the position of the permanent incisors. Retained deciduous incisors should be identified early on oral examinations. They can be removed easily and with minimal side effects the earlier they are identified.

Retained deciduous cheek teeth, "caps," are normally shed at 2.5, 3, and 4 years of age for the first, second and third premolars respectively. The caps should be removed when they are loose. Retained deciduous caps can become displaced laterally and lodge between the cheek teeth and the cheek resulting in painful, malodorous cheek pockets. Loose caps can be easily identified on oral examinations and removed with cap extractors.

In summary, the oral cavity of a young horse is ever changing. Deciduous teeth erupt and are shed to make room for the permanent teeth. The teeth crowd together forming tight junctions so they can work as one unit for grinding feedstuffs. Various developmental disorders can occur as the foal grows into adulthood. Basic dental exams should occur every six months from birth to two years of age to identify abnormalities. After two, yearly exams are adequate unless issues are identified that require more frequent care. Routine veterinary dental oral examinations can help diagnose developmental disorders early. Your veterinary dentist can document them in the dental record and formulate a treatment plan to help manage your horse's mouth, therefore providing the best care for your horse.